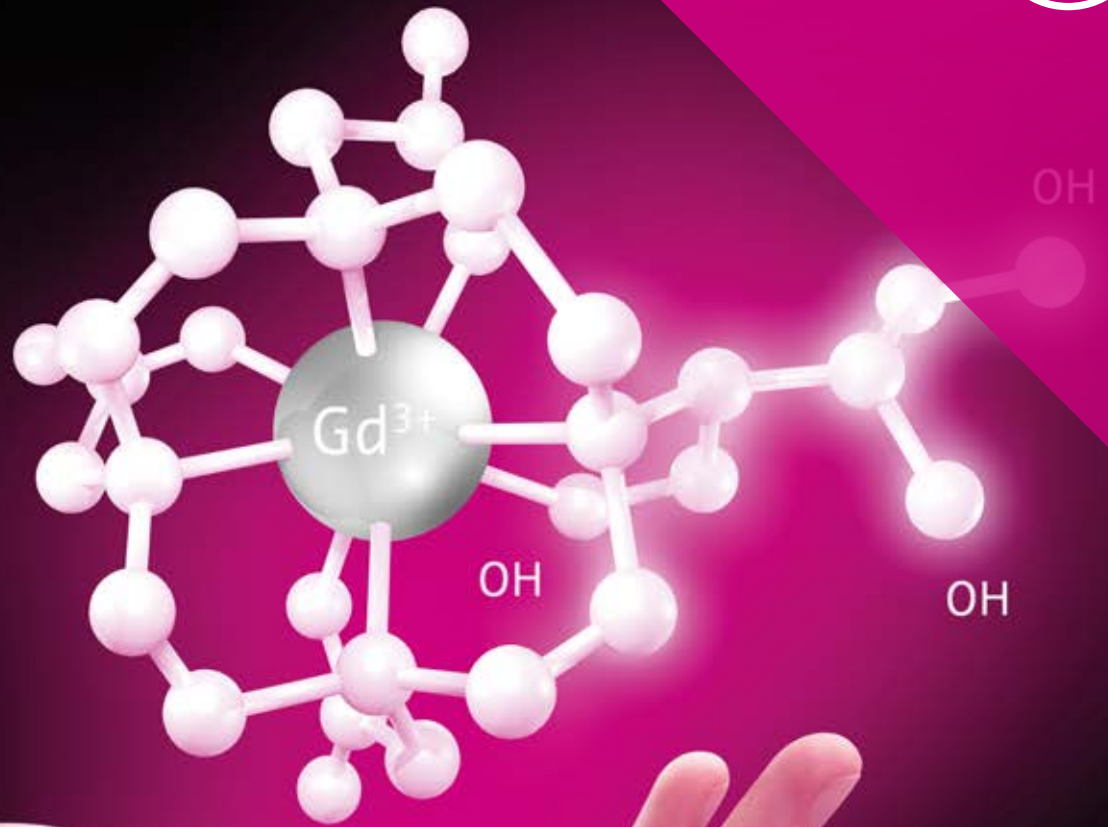



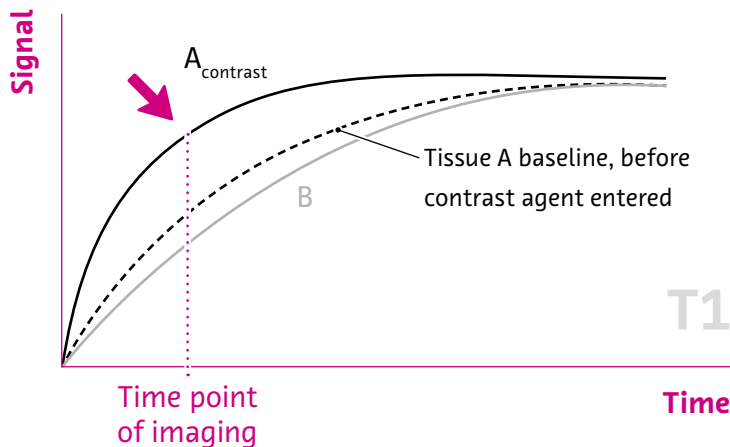
The Power of Relaxivity

Clear Direction.  From Diagnosis to Care.

Gadovist® 1.0
Gadobutrol

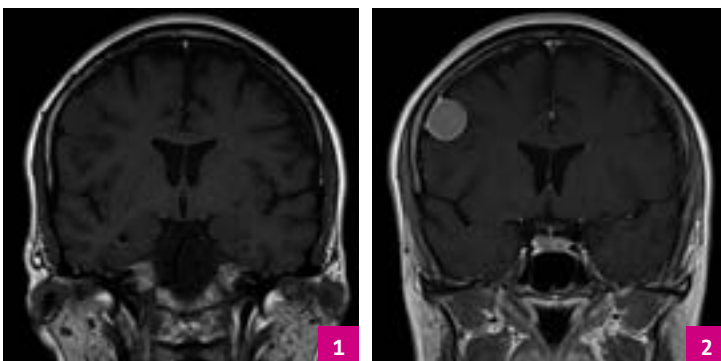
What Is Relaxivity?

- ✓ The effect of a gadolinium-based contrast agent (GBCA) to generate contrast mainly depends on its local tissue concentration and relaxivity.¹
- ✓ Relaxivity is a marker for the ability of a GBCA to enhance signal intensity on the MR image and is a prerequisite of technical efficacy of GBCAs.²



Signal enhancement by contrast media. The contrast agent only entered tissue A but did not enter tissue B.³

Adapted from Schild HH. MRI Made Easy... well almost [iOS App]. Version 1.5.1, Utrecht, The Netherlands: BestApps BV; 2018

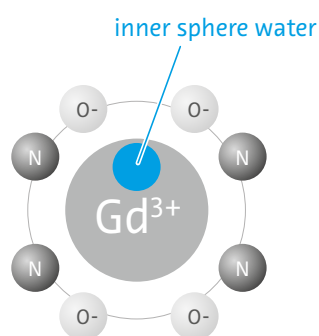


T1-weighted image without GBCA (1), T1-weighted image with GBCA (2).

Images courtesy of PD Dr. med. Alexander Huppertz, Klinikum Ernst von Bergmann, Potsdam, Germany

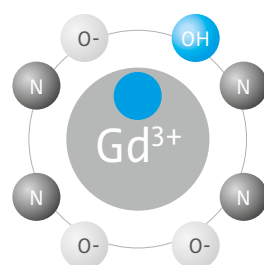
Molecular Structure Influences Relaxivity

- ✓ High relaxivity can be generated by additional hydroxy groups leading to better interaction with bulk water and higher water exchange rates⁴⁻⁶



Gadoterate meglumine

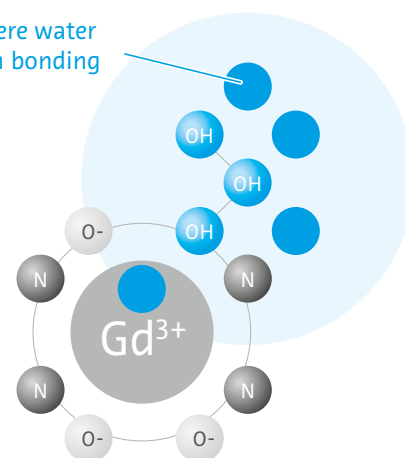
- A) **3.6** (3.4–3.8)
- B) **3.9** (± 0.1)
- C) **3.3** (± 0.1)



Gadoteridol

- A) **4.1** (3.9–4.3)
- B) **4.3** (± 0.5)
- C) **3.8** (± 0.1)

second sphere water
by hydrogen bonding



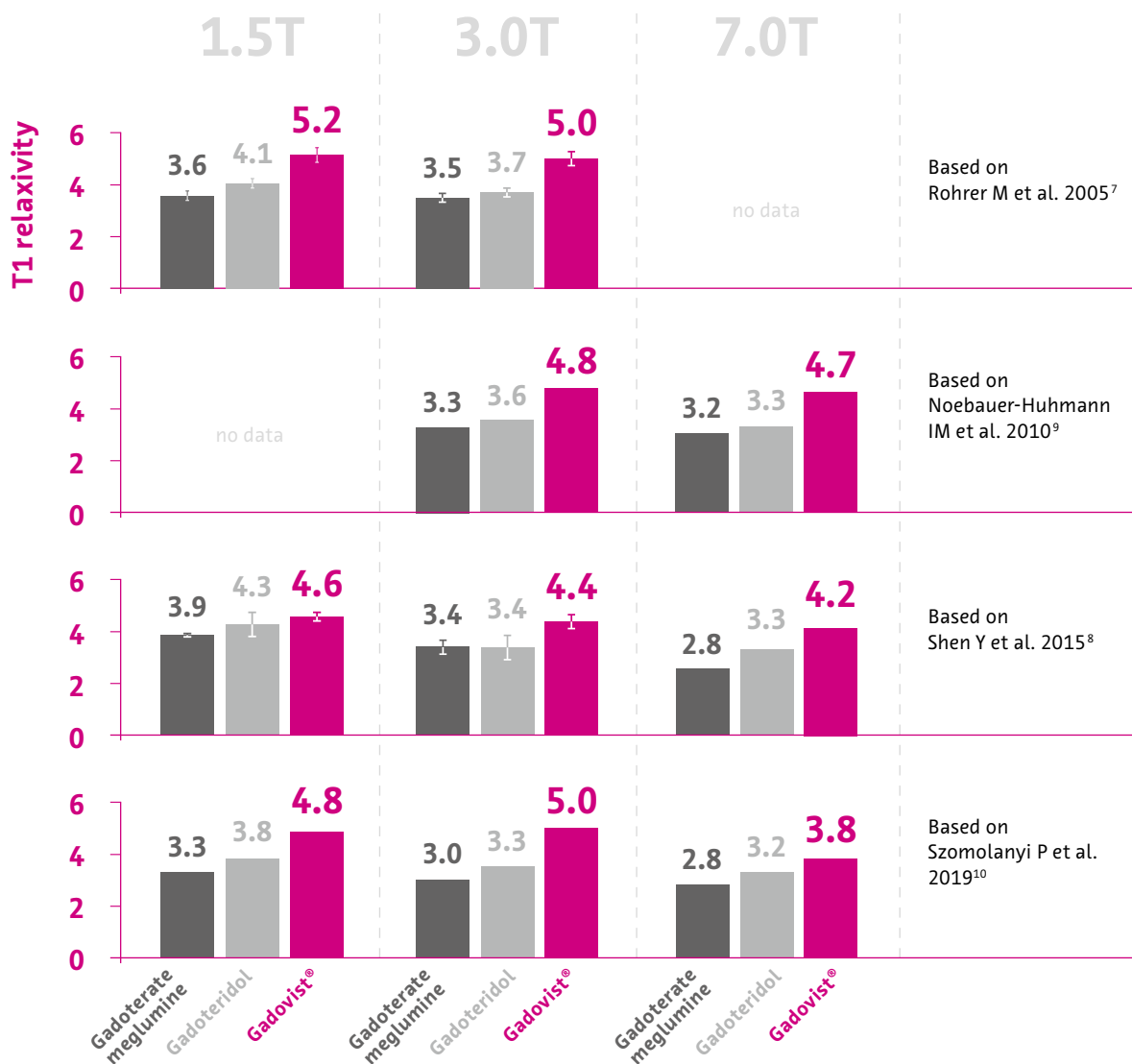Gadovist®/Gadobutrol

- A) **5.2** (4.9–5.5)
- B) **4.6** (± 0.1)
- C) **4.8** (± 0.1)

T1 relaxivity ($L \text{ mmol}^{-1} \text{ s}^{-1}$) at 1.5T in A) bovine plasma at 37°C (based on Rohrer M et al. 2005)⁷, B) human whole blood at 37°C (based on Shen Y et al. 2015)⁸, and C) human plasma at 37°C (based on Szomolanyi P et al. 2019)¹⁰

➤ High relaxivity due to molecular properties of Gadovist®^{5,7}

Relaxivity of Gadovist® Compared to Other Macrocylic GBCAs



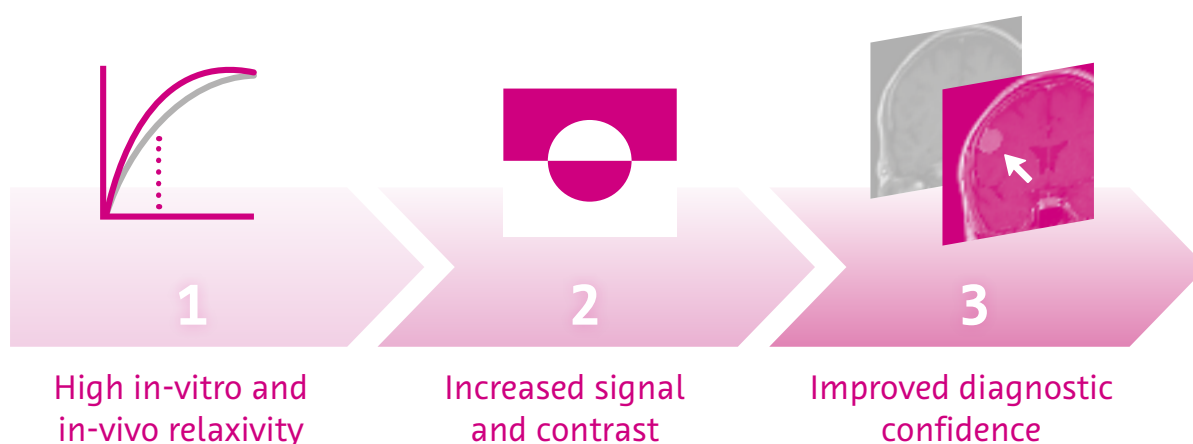
While the absolute relaxivity values differ from study to study due to different measurement conditions, the order of relaxivity values is consistent between studies⁷⁻¹⁰

➤ Gadovist® shows consistently high relaxivity values

Why Is Relaxivity Important?

- ✓ Higher relaxivity could result in*
 - increased signal on T1-weighted images^{11,12}
 - enhanced image quality¹²
 - improved diagnostic confidence^{13,14}
- ✓ In steady-state imaging, GBCA distribution in tissue** and imaging time point contributes to signal enhancement: higher relaxivity leads to higher signal increase¹
- ✓ In dynamic imaging (e.g. MRA), the image is obtained while the GBCA passes through a certain area: local tissue concentration, injected dose and relaxivity impact the signal

Relationship between higher relaxivity and improved image quality and diagnostic confidence in three steps^{11,12}



* at equal contrast dose

** e.g. leakage due to blood brain barrier disruption or vascularization

How to Investigate the Clinical Effect of Relaxivity

- ✓ Direct comparison studies have been conducted to investigate the effect of the high relaxivity of Gadovist® vs. the other macrocyclic GBCAs gadoteridol and gadoterate meglumine
- ✓ Injected dose and imaging parameters need to be kept identical in intra-individual trials when investigating possible effects of relaxivity differences between two GBCAs

In 3 out of 4 direct comparison trials against gadoteridol,¹³⁻¹⁶ Gadovist® showed either:

- Greater CE, improved sensitivity and accuracy for detection of malignant disease in CNS.¹³
- Non-inferiority of a single dose of Gadovist® to a double dose of gadoteridol.¹⁴
- Significantly superior CE characteristics for Gadovist® in primary and secondary brain tumors.¹⁶

In 2 out of 3 direct comparison trials against gadoterate meglumine,¹⁷⁻¹⁹ Gadovist® showed either:

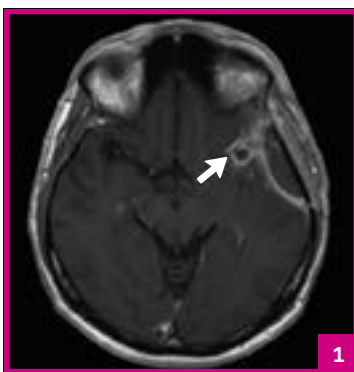
- Better visualization of enhancing brain lesions.¹⁸
- Increased enhancement in MS lesions.¹⁹

Comparison Studies CNS

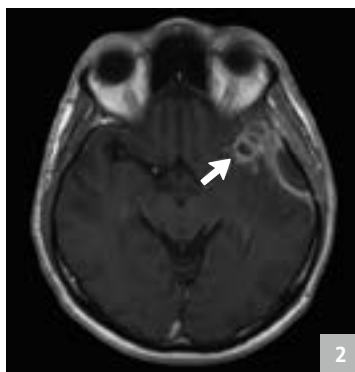
> Gutierrez JE et al. 2015 – A prospective, multicenter, randomized, double-blind, intra-individual comparison study.

Gadovist® Demonstrates Greater CE, Improved Sensitivity and Accuracy for Detection of Malignant Disease vs. Gadoteridol in CNS¹³

- ✓ Improved differentiation of malignant vs. benign lesions attributed to higher relaxivity of Gadovist®
- ✓ Gadovist® shows significantly higher sensitivity and accuracy for detection of malignancy compared to gadoteridol without change in specificity.



Gadovist®



Gadoteridol

Follow-up evaluation for a glioma diagnosis.

- 1 Gadovist® contrast-enhanced T1w image showed enhancement with sharp delineation of the anatomic involvement, which was diagnosed as residual / recurrent high-grade glial tumor.
- 2 Gadoteridol contrast-enhanced T1w image shows less sharp rings of enhancement that were characterized as infection rather than tumor.

	Gadovist®	Gadoteridol	Nominal P-value
Sensitivity (n = 93)	66.7 %	60.2 %	P = 0.014
Specificity (n = 199)	97.5 %	97.5 %	P = 1.000
Accuracy (n = 292)	87.7 %	85.6 %	P = 0.034

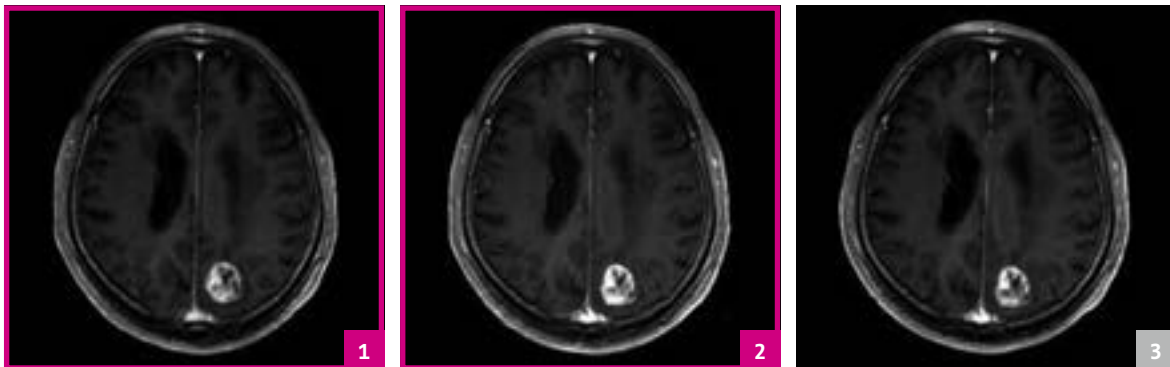Sensitivity, specificity, and accuracy in determination of malignancy for combined Gadovist® contrast-enhanced vs. combined gadoteridol contrast-enhanced imaging (majority reader diagnosis). Full analysis set (n = 336).

> “Increase in diagnostic performance may be a result of improved enhancement in poorly enhancing malignant lesions”

- Katakami N et al. 2011 – A phase II/III, multicenter, single-blind, randomized, controlled, crossover, intra-individual comparison study.

Single Dose of Gadovist® was Shown to be Non-inferior to a Double Dose of Gadoteridol¹⁴

Image Contrast



Gadovist® 0.1 mmol/kg b.w.

Gadovist® 0.2 mmol/kg b.w.

Gadoteridol 0.2 mmol/kg b.w.

Performance in Stereotactic Radiosurgery Planning

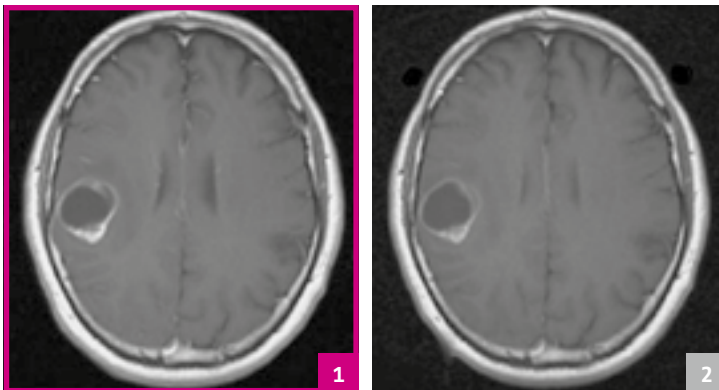
0.2 mmol/kg gadoteridol vs. dose of Gadovist®	0.1 mmol/kg b.w. # patients (%)	0.2 mmol/kg b.w. # patients (%)
Gadovist® better than gadoteridol	26/65 (40.0)	22/62 (36.5)
Gadoteridol better than Gadovist®	15/65 (23.1)	10/62 (16.1)
Both agents the same	24/65 (36.9)	30/62 (48.4)

- Gadovist® shows non-significant improvement for radiosurgery planning vs. gadoteridol

> **Koenig M et al. 2013** – A prospective, single-center, randomized, intra-individual comparison study.

Significantly Superior CE Characteristics For Gadovist® in Primary and Secondary Brain Tumors¹⁶

- ✓ Intra-individual comparison showed preference of gadobutrol over gadoteridol
- ✓ Quantitative results demonstrated significant superiority in lesion-to-brain contrast



Gadovist®

Gadoteridol

A 49-year-old male patient with metastasis of laryngeal squamous cell carcinoma. T1-weighted SE images after Gadovist® (1) and gadoteridol (2). There is a higher T1 signal with Gadovist® leading to a better enhancement of the tumor margin follow-up evaluation for a glioma diagnosis.

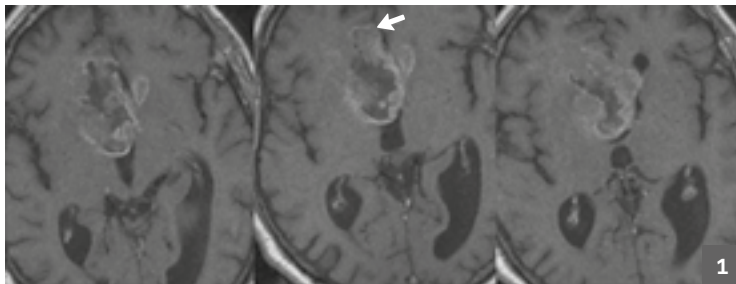
Significantly superior contrast in a routine MRI protocol

Overall preference (FAS**), N = 51	Reader 1, N (%)	Reader 2, N (%)
	P = 0.0046	P = 0.002
Gadovist® better than gadoteridol	36/51 (71%)	34/51 (67%)*
Gadoteridol better than Gadovist®	15/51 (29%)	9/51 (18%)*

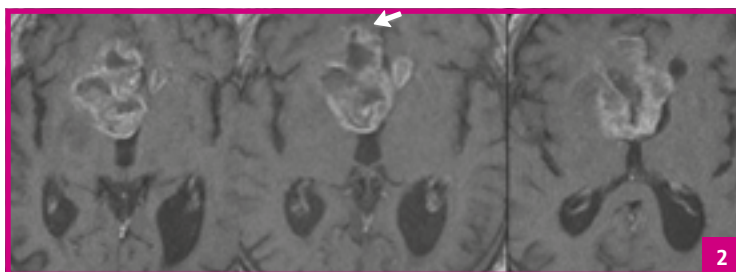
Adapted from Koenig M, et al. 2013¹⁶
* N = 8 were rated with no preference; ** Full analysis set

- Anzalone N et al. 2013 – A prospective, multicenter, randomized, open-label, intra-individual comparison study.

Better Visualization of Enhancing Brain Lesions by Gadovist® vs. Gadoterate Meglumine¹⁸



Gadoterate meglumine



Gadovist®

A 69-year-old male patient with butterfly glioma (glioblastoma WHO grade IV). Three consecutive T1-weighted images after a single dose (0.1 mmol/kg body weight) of gadoterate meglumine (1) and Gadovist® (2).

Overall preference*	# assessments (%)
Gadovist® better than gadoterate meglumine	131/199** (66)
Gadoterate meglumine better than Gadovist®	68/199** (34)

* Three independent blinded readers assessed off-site their overall diagnostic preference (primary efficacy parameter) based on a matched pairs approach.

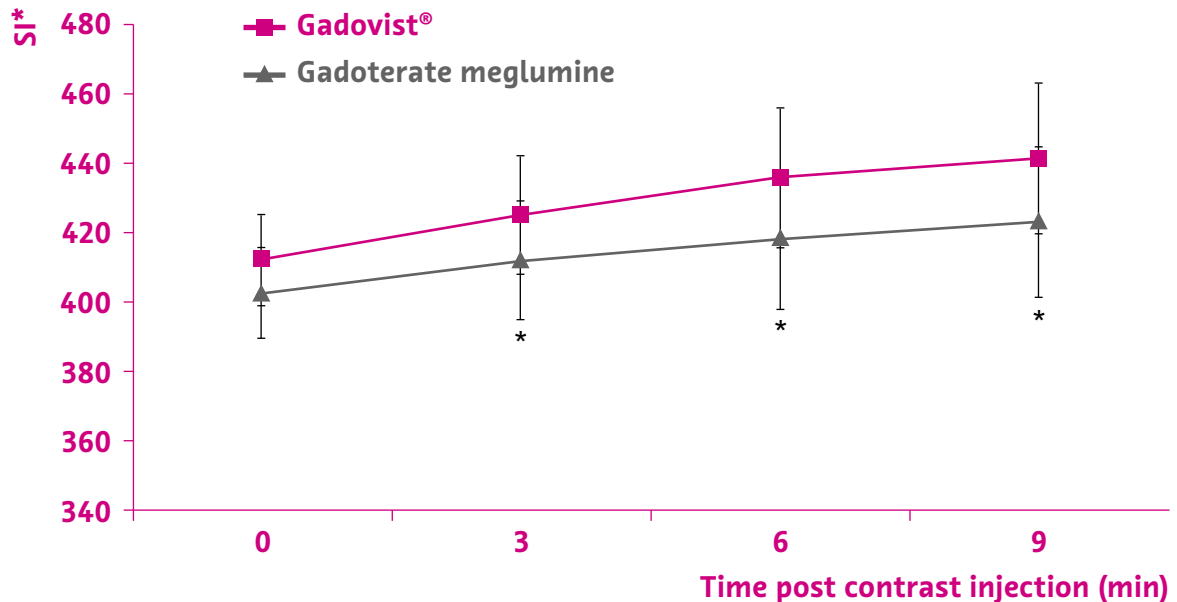
** Assessments in which a preference for either agent was expressed (P<0.001). No preference recorded in a further 175.

Gadovist® provided

- Better contrast enhancement of lesions than gadoterate meglumine (P<0.001)
- Higher lesion-to-brain signal (P<0.001)
- 9% difference in relative enhancement (P<0.001)

➤ **Saake M et al. 2016** – A prospective, multicenter, randomized, intra-individual comparison study.

Increased Enhancement in MS Lesions With Gadovist® vs. Gadoterate Meglumine¹⁹



Measured SI of MS lesions after GBCA injection. Asterisk indicates statistically significant difference ($p < 0.05$). Bars show standard deviations. Gadovist® generated higher lesion SI at all time points.

- Significantly higher mean lesion enhancement for Gadovist® ($p = 0.05$)
- Subjective preference showed non-significant tendency in favor of Gadovist®

* SI = Signal Intensity

Approved uses of Macrocyyclic Agents

Exam type	Gadovist® ²²	Gadoteridol ²³	Gadoterate meglumine ²⁴
CNS	✓	✓	✓
Head & neck		✓	
MRA	✓		
Breast	✓		
Kidney	✓		
Perfusion Studies	✓		

Gadovist® is uniquely indicated “for detection of very small lesions and for visualization of tumors that do not readily take up contrast media.”^{22†}

- ✓ indicated for use in patients of all ages, including term newborns
- ✓ indicated for use in adults and children 2 years of age and older
- ✓ indicated for use in adults **only**

Summary

- ✓ With its high relaxivity, Gadovist® leads to a higher signal intensity and contrast in CNS MRI than gadoterate meglumine and gadoteridol enabling better detection, delineation and characterization of CNS lesions.^{7-10,13,14,16,18,19}
- ✓ Higher relaxivity could result in*
 - increased signal on T1-weighted images^{11,12}
 - enhanced image quality¹²
 - improved diagnostic confidence^{13,14}

➤ Gadovist® contrast-enhanced CNS MRI can lead to a higher diagnostic confidence both at 1.5T, 3T and 7T via better image quality and higher sensitivity/specificity.^{7-10,13,14,16,18-22}

* at equal contrast dose

† For complete product information, please refer to the respective product monograph

References

- Balzer T. in , Reimer P, Parizel P, et al.**
Clinical MR Imaging / A practical approach, page 38
ISBN 3-540-64098-3
- Tóth É, Helm L, Merbach A.**
Relaxivity of gadolinium(III) complexes: Theory and mechanism. In: Merbach A, Helm L, Tóth É, eds. The chemistry of contrast agents in medical magnetic resonance imaging. Second Edition ed: John Wiley & Sons, Ltd; 2013:25–81.
- Schild HH.**
MRI Made Easy... well almost [iOS App]. Version 1.5.1, Utrecht, The Netherlands: BestApps BV; 2018.
- Caravan P.**
Strategies for increasing the sensitivity of gadolinium based MRI contrast agents. Chem Soc Rev. 2006;35(6):512–523.
- De León-Rodríguez LM, Martins AF, Pinho MC, et al.**
Basic MR relaxation mechanisms and contrast agent design. J Magn Reson Imaging. 2015;42(3):545–565.
- Botta M.**
Second Coordination Sphere Water Molecules and Relaxivity of Gadolinium(III) Complexes: Implications for MRI Contrast Agents. Eur J Inorg Chem. 2000;399-407
- Rohrer M, Bauer H, Mintonovitch J, et al.**
Comparison of magnetic properties of MRI contrast media solutions at different magnetic field strengths. Invest Radiol. 2005;40(11):715–724.
- Shen Y, Goerner FL, Snyder C, et al.**
T1 relaxivities of gadolinium-based magnetic resonance contrast agents in human whole blood at 1.5, 3, and 7 T. Invest Radiol. 2015;50(5):330–338.
- Noebauer-Huhmann IM, Szomolanyi P, Juras V, et al.**
Gadolinium-based magnetic resonance contrast agents at 7 Tesla: in vitro T1 relaxivities in human blood plasma. Invest Radiol. 2010;45(9):554–558.
- Szomolanyi P, Rohrer M, Frenzel T, et al.**
Comparison of the relaxivities of macrocyclic gadoliniumbased contrast agents in human plasma at 1.5, 3 and 7 T, and blood at 3 T. Invest Radiol. 2019 [Epub ahead of print].
- Kanal E, Maravilla K, Rowley HA.**
Gadolinium contrast agents for CNS imaging: current concepts and clinical evidence. AJNR Am J Neuroradiol. 2014;35(12):2215–2226.
- Anzalone N, Essig M, Lee SK, et al.**
Optimizing contrast-enhanced magnetic resonance imaging characterization of brain metastases: relevance to stereotactic radiosurgery. Neurosurgery. 2013;72(5):691–701.
- Gutierrez JE, Rosenberg M, Seemann J, et al.**
Safety and Efficacy of Gadobutrol for Contrast-enhanced Magnetic Resonance Imaging of the Central Nervous System: Results from a Multicenter, Double-blind, Randomized, Comparator Study. Magn Reson Insights. 2015;8:1–10.
- Katakami N, Inaba Y, Sugata S, et al.**
Magnetic resonance evaluation of brain metastases from systemic malignancies with two doses of gadobutrol 1.0 m compared with gadoteridol: a multicenter, phase ii/iii study in patients with known or suspected brain metastases. Invest Radiol. 2011;46(7):411–418.

- 15 Maravilla KR, Smith MP, Vymazal J, et al.**
Are There Differences between Macrocyclic Gadolinium Contrast Agents for Brain Tumor Imaging? Results of a Multicenter Intraindividual Crossover Comparison of Gadobutrol with Gadoteridol (the TRUTH Study). *AJNR Am J Neuroradiol.* 2015;36(1):14–23.
- 16 Koenig M, Schulte-Altedorneburg G, Piontek M, et al.**
Intra-individual, randomised comparison of the MRI contrast agents gadobutrol versus gadoteridol in patients with primary and secondary brain tumours, evaluated in a blinded read. *Eur Radiol.* 2013;23(12):3287–3295.
- 17 Maravilla KR, San-Juan D, Kim SJ, et al.**
Comparison of Gadoterate Meglumine and Gadobutrol in the MRI Diagnosis of Primary Brain Tumors: A Double-Blind Randomized Controlled Intraindividual Crossover Study (the REMIND Study). *AJNR Am J Neuroradiol.* 2017;38(9):1681–1688.
- 18 Anzalone N, Scarabino T, Venturi C, et al.**
Cerebral neoplastic enhancing lesions: multicenter, randomized, crossover intraindividual comparison between gadobutrol (1.0M) and gadoterate meglumine (0.5M) at 0.1 mmol Gd/kg body weight in a clinical setting. *Eur J Radiol.* 2013;82(1):139–145.
- 19 Saake M, Langner S, Schwenke C, et al.**
MRI in multiple sclerosis: an intra-individual, randomized and multicentric comparison of gadobutrol with gadoterate meglumine at 3 T. *Eur Radiol.* 2016;26(3):820–828.
- 20 Voth M, Attenberger UI, Luckscheiter A, et al.**
“Number needed to read” – how to facilitate clinical trials in MR-angiography. *Eur Radiol.* 2011;21(5):1034–1042.
- 21 Loewe C, Arnaiz J, Krause D, et al.**
MR Angiography at 3 T of Peripheral Arterial Disease: A Randomized Prospective Comparison of Gadoterate Meglumine and Gadobutrol. *AJR Am J Roentgenol.* 2015;204(6):1311–1321.
- 22** Gadovist® 1.0 Product Monograph. March 5, 2018.
- 23** Gadoteridol Product Monograph. March 9, 2018.
- 24** Gadoterate meglumine Product Monograph. April 23, 2018.

GADOVIST® 1.0 mmol/mL solution for injection. **Composition:** GADOVIST 1.0 is a clear, sterile, aqueous solution. Each mL of GADOVIST 1.0 contains 604.72 mg (1.0 mmol) of gadobutrol, 1.211 mg trometamol, 0.013 mg sodium (0.00056 mmol), and 0.513 mg calcium sodium butrol in water for injection. The pH of GADOVIST 1.0 is adjusted to between 6.6 and 8.0 with hydrochloric acid. **Indications:** GADOVIST 1.0 (gadobutrol) is a medicinal product for diagnostic use only. GADOVIST 1.0 (gadobutrol) is indicated in adults and children of all ages including term newborns for: contrast enhancement during cranial and spinal MRI investigations and for contrast-enhanced magnetic resonance angiography (CE-MRA); contrast enhanced MRI of the breast to assess the presence and extent of malignant breast disease, and MRI of the kidney. GADOVIST 1.0 is particularly suited for cases where the exclusion or demonstration of additional pathology may influence the choice of therapy or patient management, for detection of very small lesions and for visualization of tumors that do not readily take up contrast media. GADOVIST 1.0 is also suited for perfusion studies for the diagnosis of stroke, detection of focal cerebral ischemia and tumor perfusion. **Contraindications:** GADOVIST 1.0 should not be administered to patients who have experienced a life-threatening reaction to GADOVIST 1.0 previously. **Serious warnings and precautions for use:** Gadolinium-based contrast agents (GBCAs) increase the risk for Nephrogenic Systemic Fibrosis (NSF) in patients with: chronic severe renal insufficiency (glomerular filtration rate <30 mL/min/1.73m²), or acute renal failure / acute kidney injury. In these patients, avoid use of GBCAs unless the diagnostic information is essential and not available with noncontrast-enhanced magnetic resonance imaging (MRI). NSF may result in fatal or debilitating systemic fibrosis affecting the skin, muscle, and internal organs. Screen all patients for renal dysfunction by obtaining a history and/or laboratory tests. When administering a GBCA, do not exceed the recommended dose and allow a sufficient period of time for elimination of the agent from the body prior to any readministration. **Adverse reactions:** Patients with a history of previous reaction to contrast media, allergic disorders or bronchial asthma suffer more frequently from hypersensitivity reactions than others. As with other contrast media, delayed allergoid reactions occurring hours or days after administration have been observed, though rarely. Anaphylactoid reactions may occur. Transient sensations of taste or smell perversion may occur during or immediately after injection of GADOVIST 1.0.

Clear Direction.  From Diagnosis to Care.

The patient data that appears in this document is actual health information but all personal identifiers have been removed or otherwise anonymized. No personally identifiable information is shown.

Bayer, the Bayer Cross and Gadovist are trademarks owned by and/or registered to Bayer in the U.S. and/or other countries. Other trademarks and company names mentioned herein are properties of their respective owners and are used herein solely for informational purposes. No relationship or endorsement should be inferred or implied.

© 2019 Bayer. This material may not be reproduced, displayed, modified or distributed without the express prior written consent of Bayer.



Bayer Inc.
2920 Matheson Blvd. East
Mississauga, ON L4W 5R6
Phone: (800) 268-1432
Fax: (800) 567-1710

radiologysolutions.bayer.ca